Neuro CT – What's a Good Head Exam?

Rajiv Gupta, PhD, MD

Neuroradiology
Massachusetts General Hospital
Harvard Medical School

Outline

- What we need to see?
- Routine Head CT protocols
- Dose optimization strategies
- Some newer tricks using Dual Energy CT

58 year old, new onset of neurologic symptoms

Where is the Abnormality?

CT: Equivocal for an infarct

Acute Infarct in the ACA territory

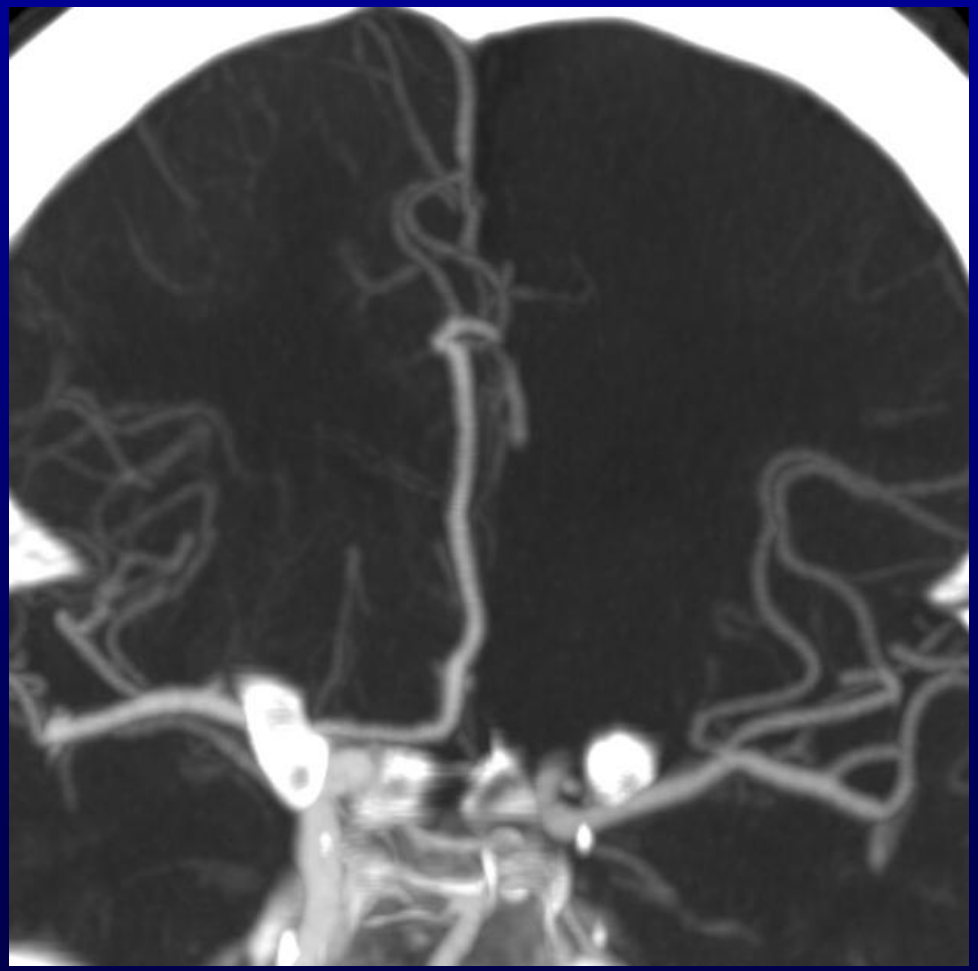

CT Angiography

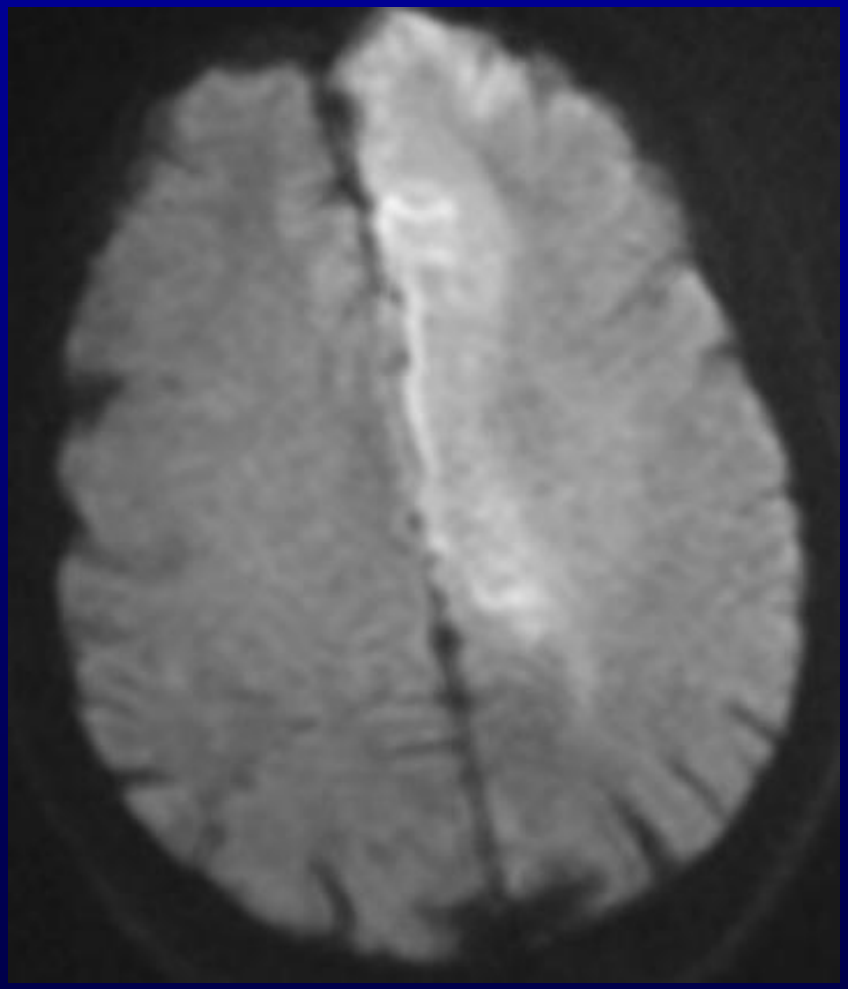

CTA SI: Reduced perfusion

DWI

Requirements

- Good gray-white differentiation

Different Case: Young patient after trauma

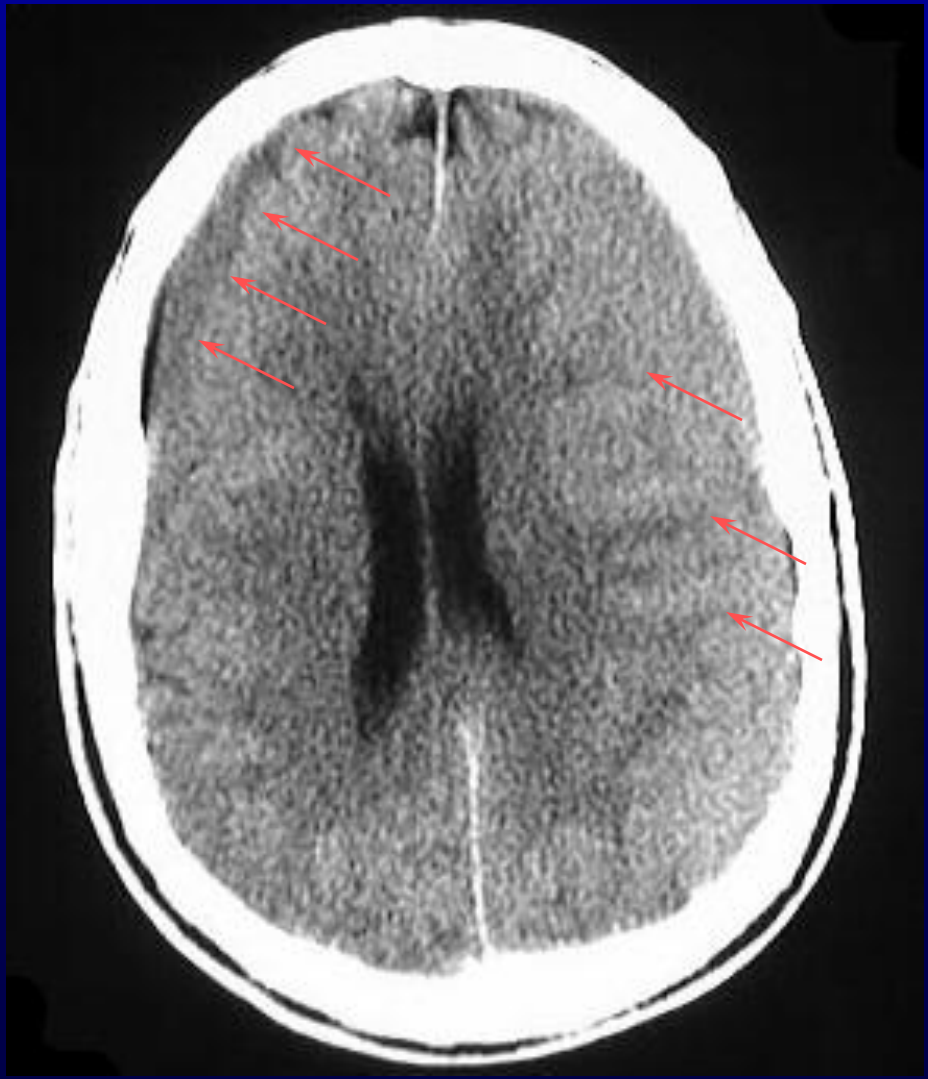

Requirements

- Good gray-white differentiation
- Proper cupping correction

11 month old female that presented with gagging after trauma to oropharynx with drum stick.

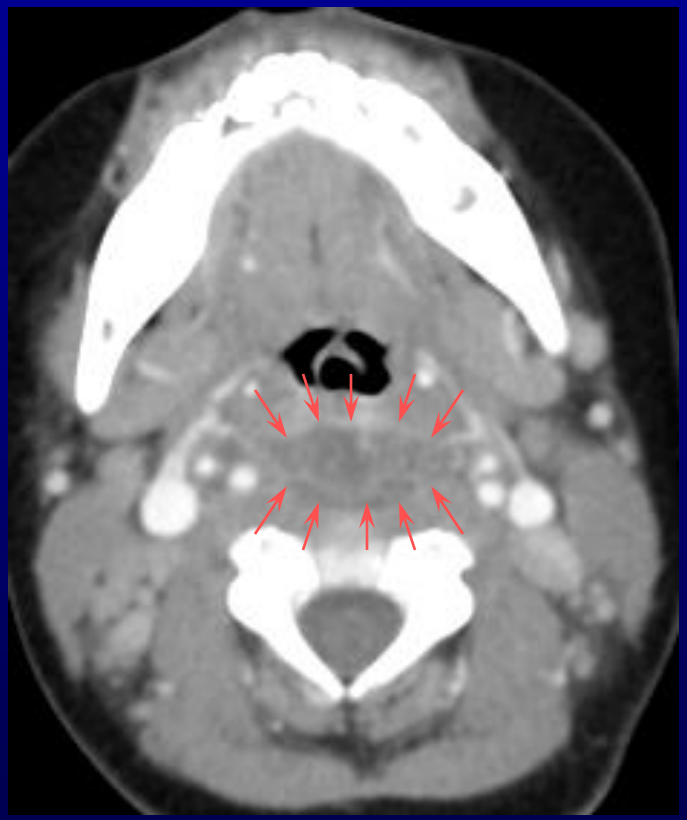

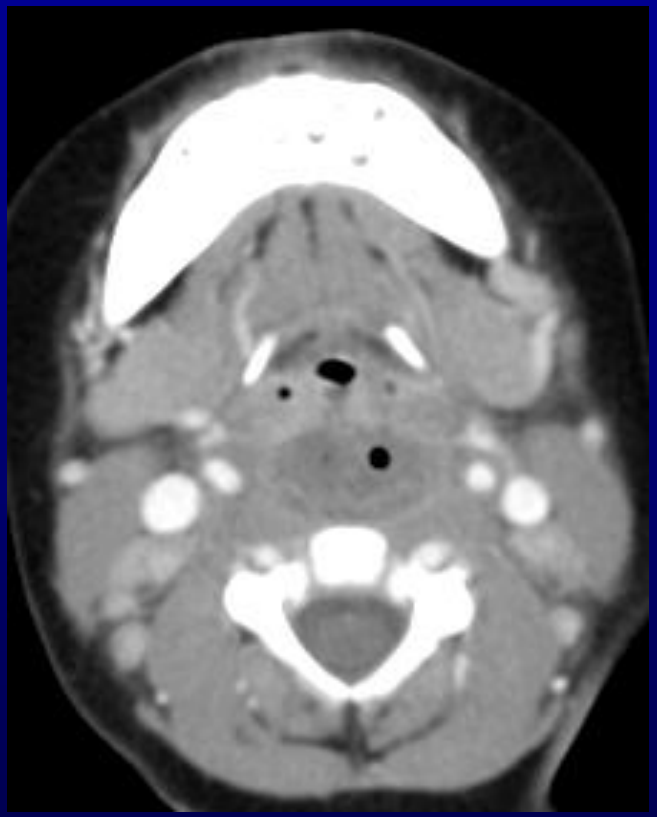

Diagnosis

- Retropharyngeal abscess
  - Etiology
    - Suppurative bacterial lymphadenitis
      - S. aureus, Strep B, oral flora
    - Foreign body perforation
    - Trauma

Requirements

- Good gray-white differentiation
- Proper cupping correction
- Good soft tissue discrimination

44 year old fell from a tree

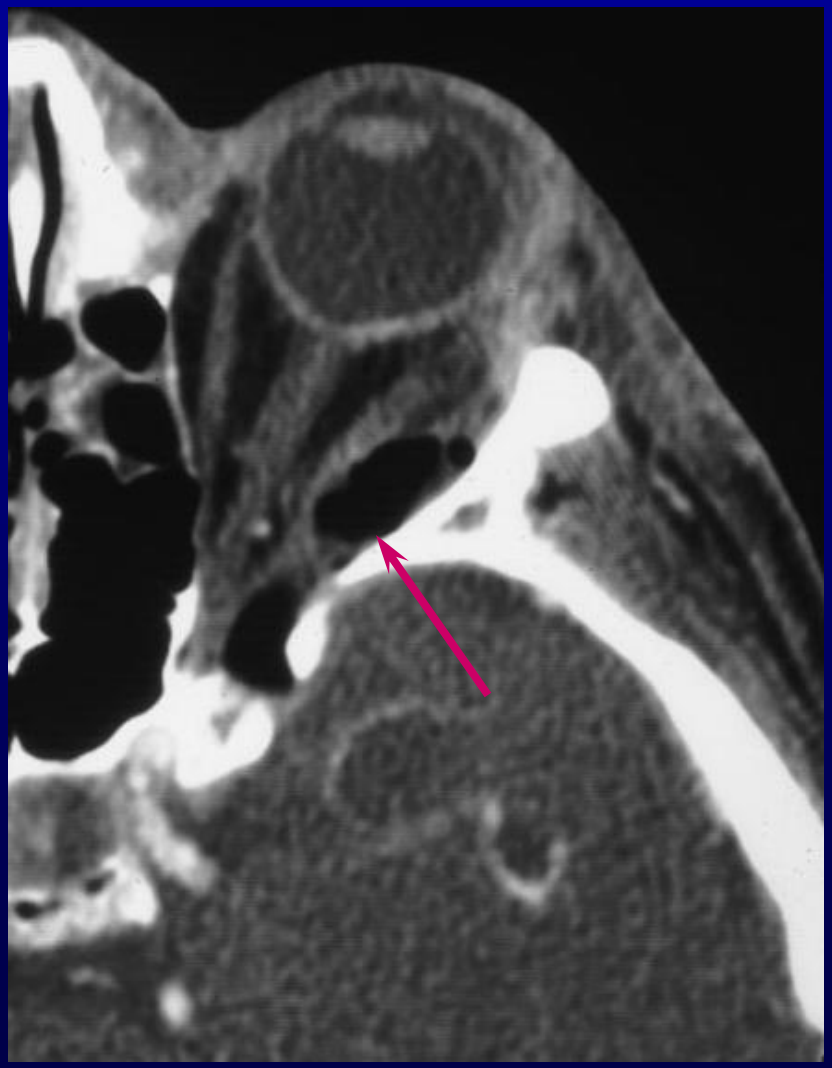

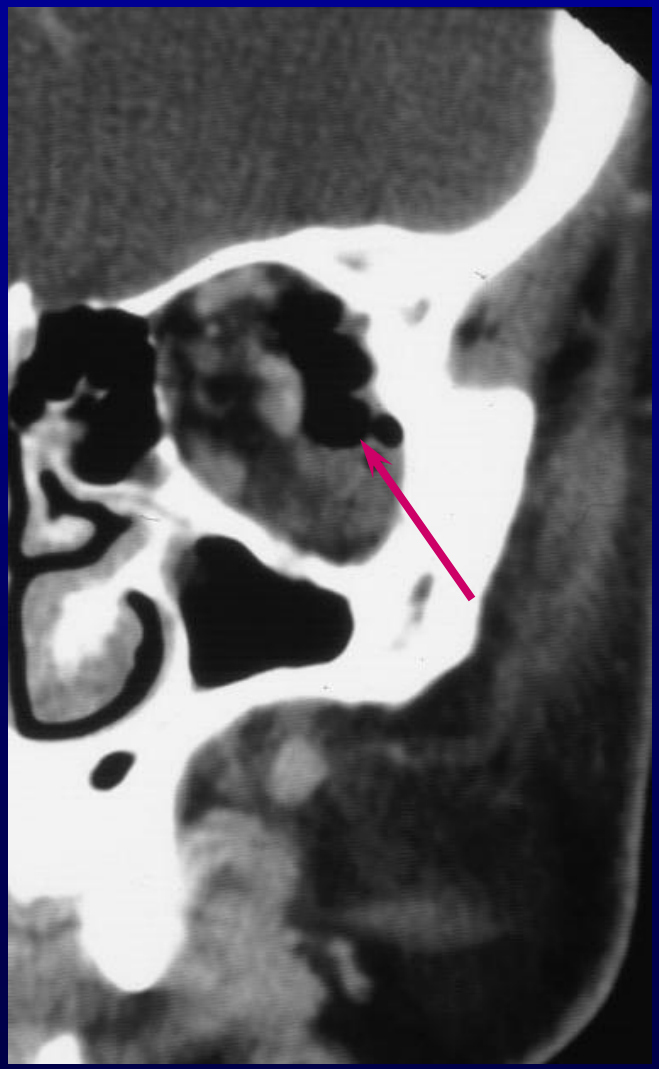

2 months later

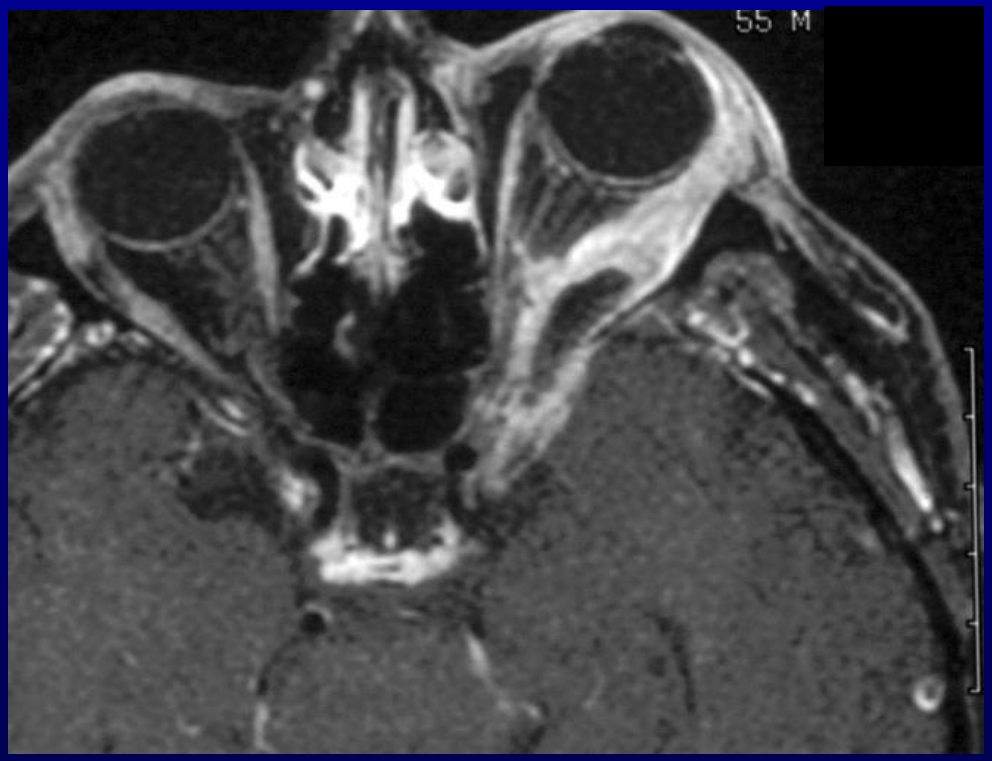

Surgical Specimen

Take-home Points:

- Wood may appear as air

- Accurate HU calibration is important

Another Case: Pencil vs Globe

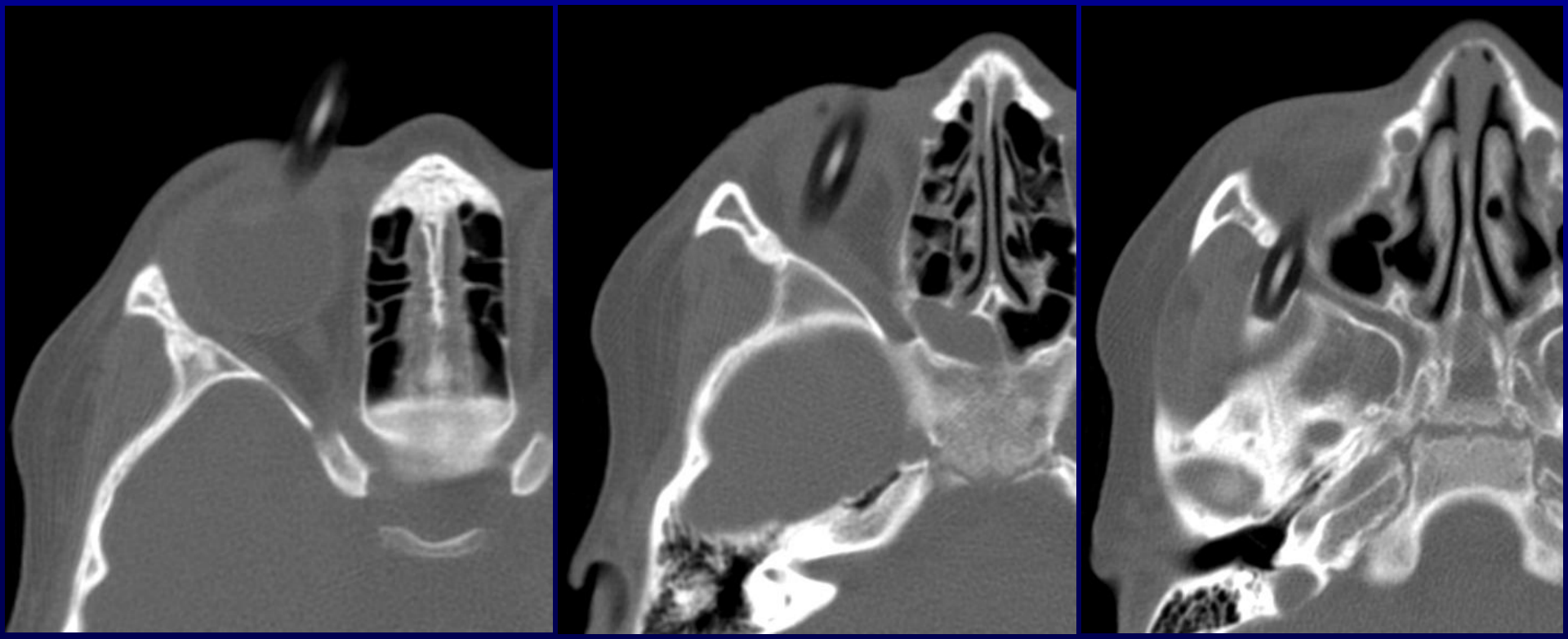

Requirements

- Good gray-white differentiation
- Proper cupping correction
- Good soft tissue discrimination
- Accurate, reliable HU calibration

History of Trauma

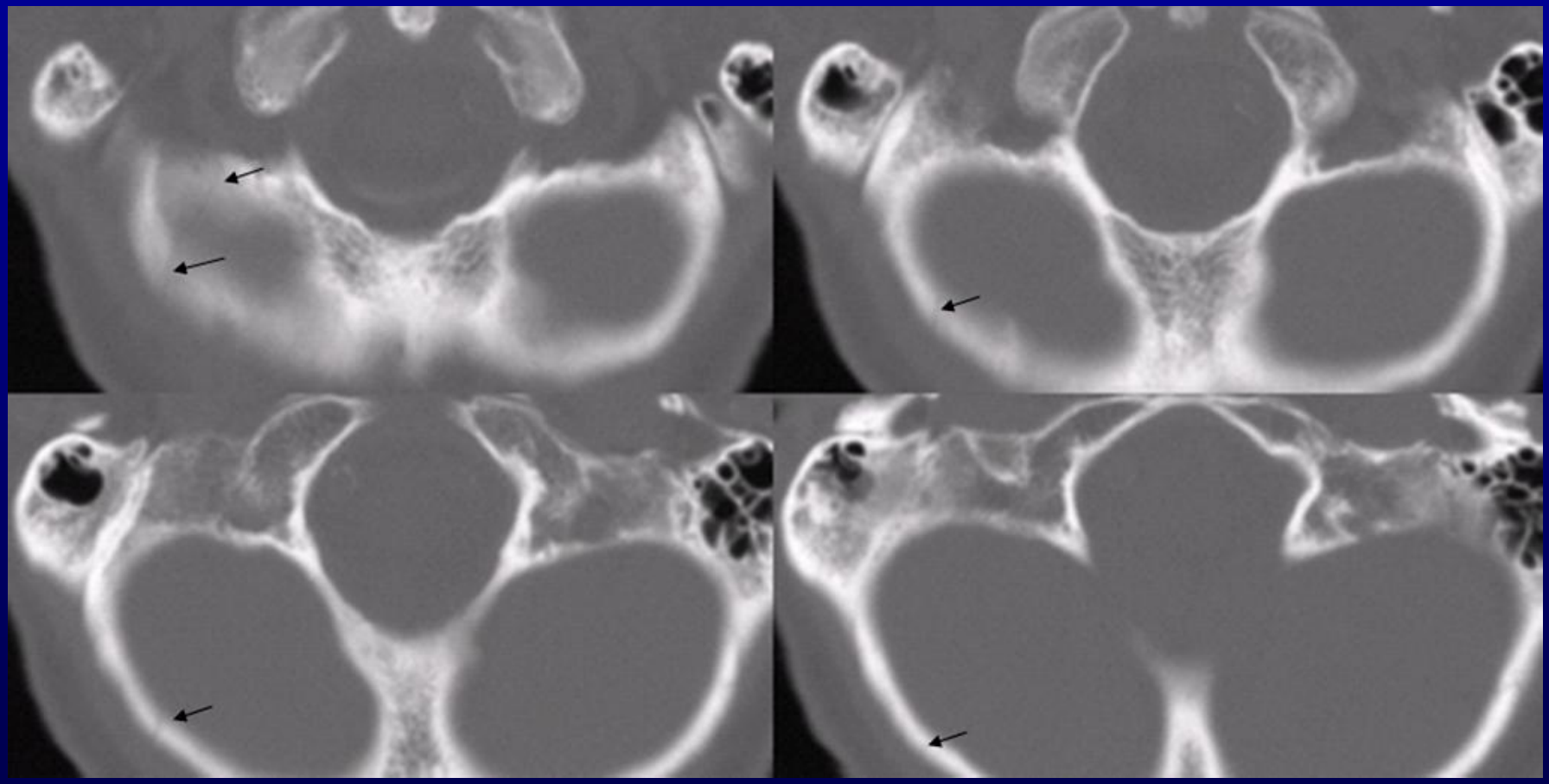

Subtle right occipital fracture, only visible on thin slices, and sharp kernel

Requirements

- Good gray-white differentiation
- Proper cupping correction
- Good soft tissue discrimination
- Accurate, reliable HU calibration
- High spatial resolution and MTF

4 year old with 2 week history of headaches, abdominal pain, anorexia and vomiting. Recent antibiotics for sinusitis.

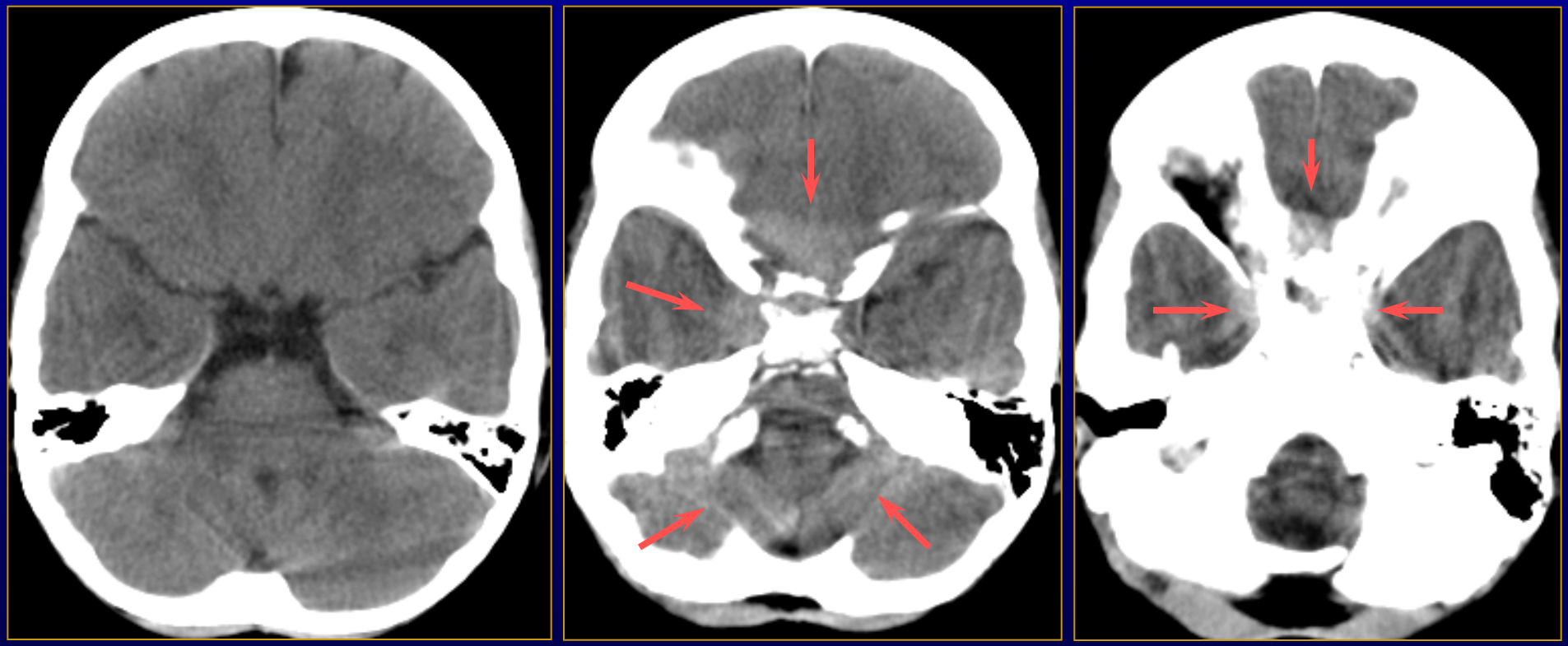

Artifact or Pathology?

Imaging 1 Week Later

CT w/ Contrast

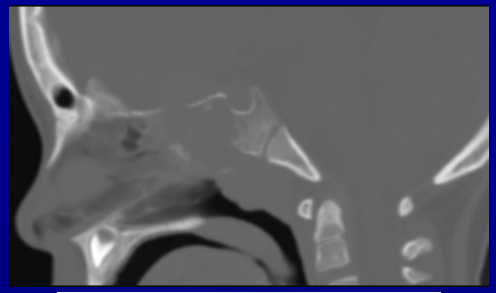

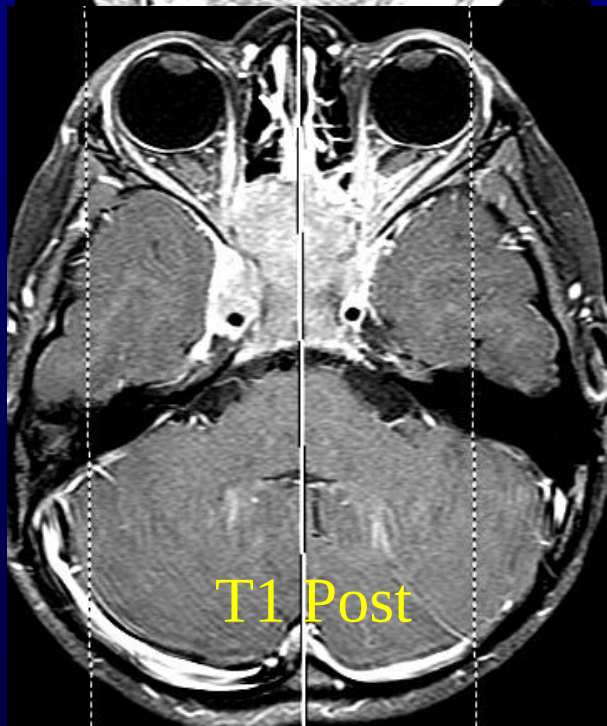

Pathology: Burkitt Lymphoma

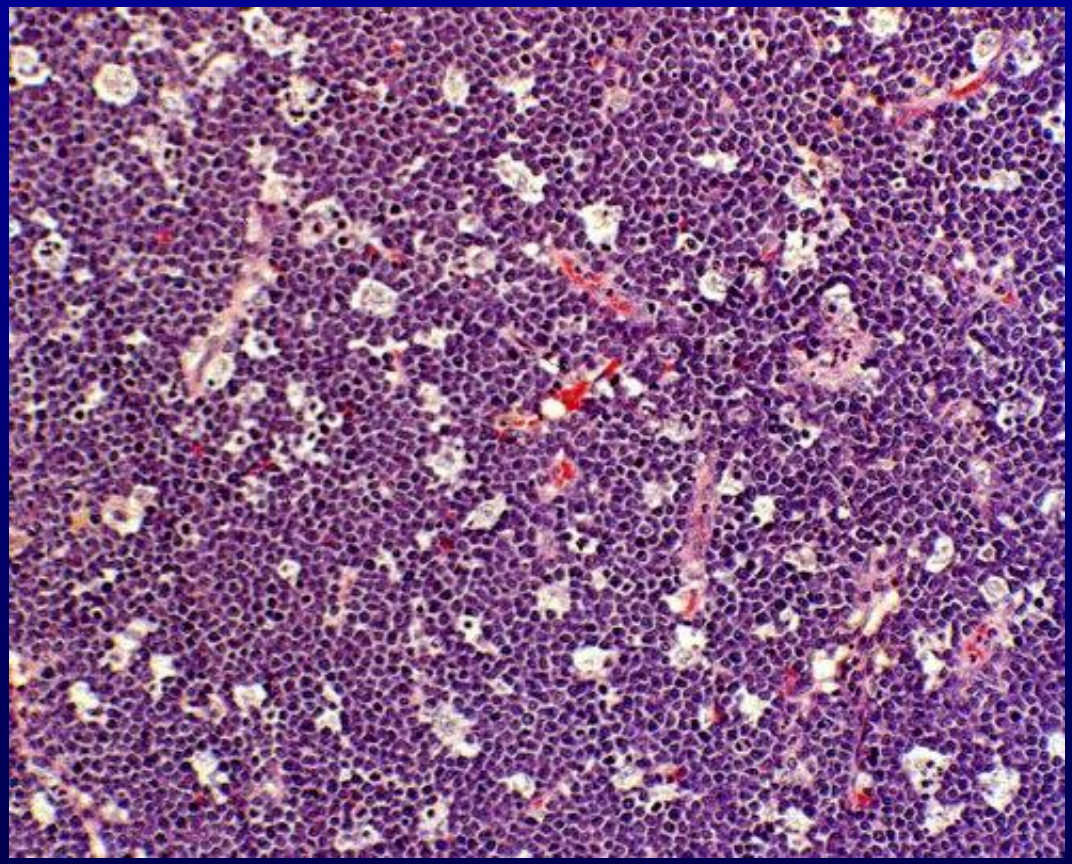

B-cell lymphoma

Requirements

- Good gray-white differentiation
- Proper cupping correction
- Good soft tissue discrimination
- Accurate, reliable HU calibration
- High spatial resolution and MTF
- Artifact-free posterior fossa and skull base

"The Chest X-ray of the Brain"

Must support quick, confident read

Main Culprits

- Poor SNR
- Poor CNR
- Poor spatial resolution
  - Improper recon kernel
  - Improper protocol
- Artifacts
  - Motion
  - Scatter
  - Beam hardening
  - Windmill
  - …

CT Artifacts

- Motion:
  - Recon assumes a stationary object
  - Problem in Pedi patients
  - Make scanners faster
    - 0.28 sec rotation
    - FLASH scanner
- Scatter:
  - Blurs the image
  - Lowers μ-effective
  - Scatter-to-primary ratio high behind bones
  - Scatter and beam hardening in same area

Beam Hardening

- Effective beam energy increases.
- Beam "hardens" as it penetrates.
- Higher E => lower μ.
- "Cupping artifact"

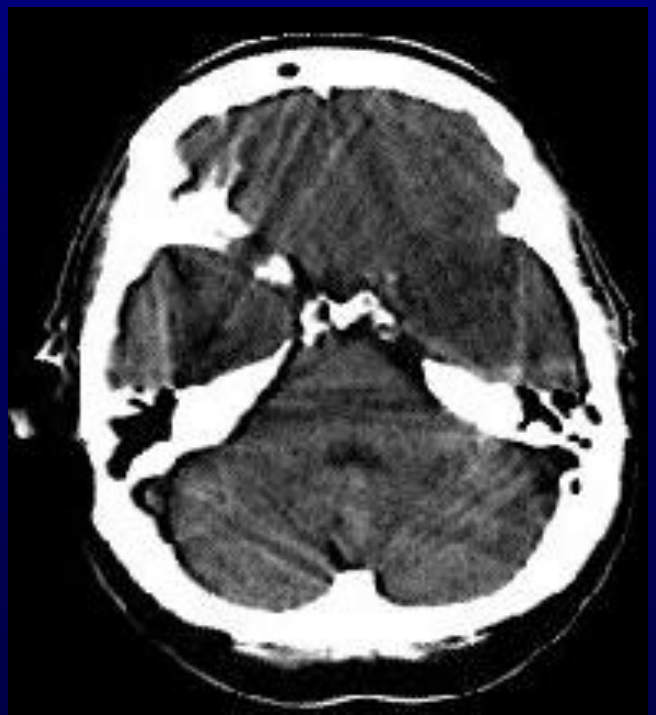

Windmill artifact

Windmill artifact

- Low pitch, overlap helices
  - Optimal ~ 0.5 - 0.66
- Minimal possible table feed
- Maximal gantry rotation speed
- Thick reconstructions
  - 1.25 by 0.625 mm
- Small focal spot
  - mA limited?

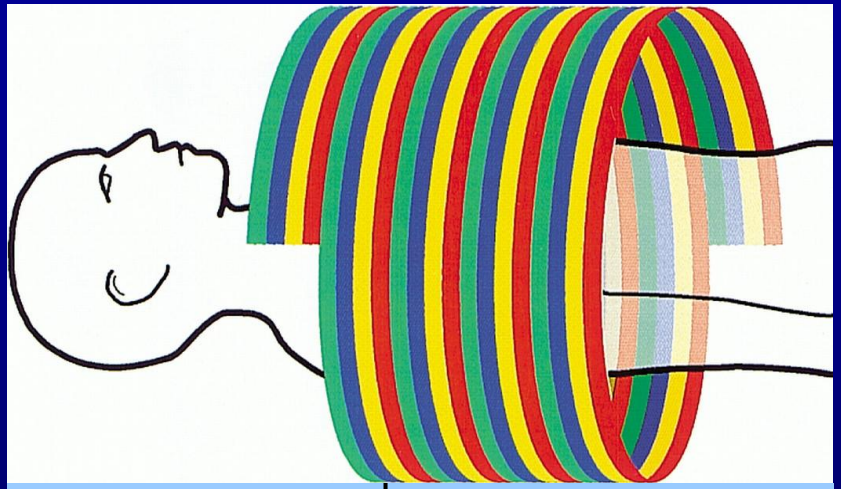

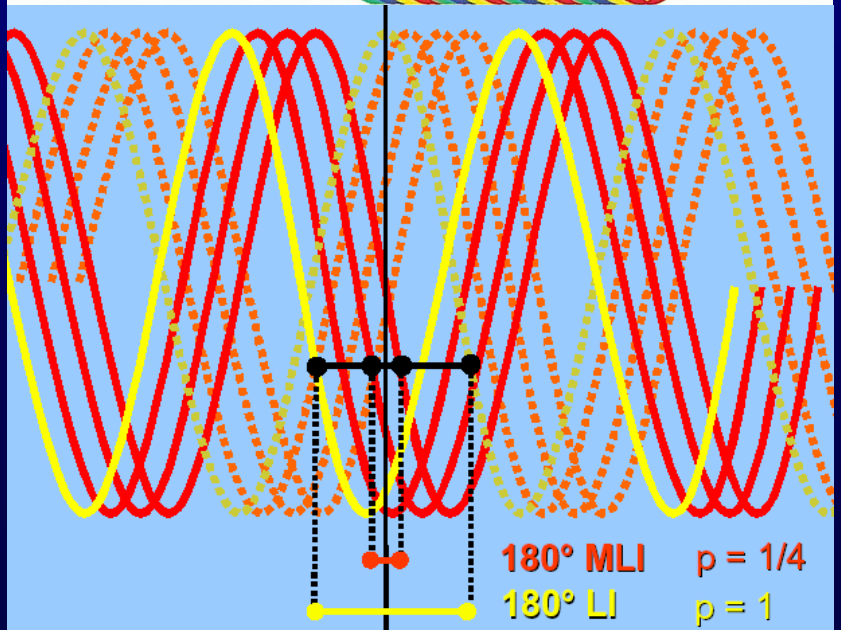

Sample MGH 64-slice Head CT Protocol (Minor Variations between Scanners)

Series Auto Transf	OFF
Mode	Helical
Time	0.7
DMPR	ON
Thickness	1.25
Pitch	0.531:1
Speed	10.62
Interval	0.625
Rotation Time	0.7
Gantry Tilt	0
SFOV	Head
KV	120
mA	250
DFOV	22
ALG	Standard

Helical, 120kV, 250mA, Pitch 0.5, ST 1.25, interval 0.625

Recon 2: 5 MM DX STD AXIALS	
Thickness	5.0
Interval	5.0
Algorithm	22
DFOV	Std

Reformats: Coronal Skull Auto w/DMPR
DFOV 22
Thickness 5.0
Interval 2.5
Window Head

Recon 3: 2.5 MM DX BONE AXIALS	
Thickness	2.5
Interval	2.5
Algorithm	Bone
DFOV	22

DECRAD CODE: CTBR-

Send dose report to PACS

CT Dose Reduction Strategies

- Use another modality!
- Optimize acquisition
  - Tailor to clinical requisition
  - Lower technique
  - Minimize artifacts
  - Dual Energy acquisition
- Optimize reconstruction / post-processing
  - FBP vs newer "iterative reconstruction" kernals
  - Filters, e.g. metal streak reduction
- Optimize readout
  - Coronal Reformats
  - Optimal PACS display
  - Appropriate window/level settings

Michael Lev, MGH

Optimizing Scan Parameters: Basic Principles

- Lowest possible mAs is proportional to:
  - Degree of intrinsic tissue contrast
  - Acceptable level of image noise
  - Noise ~ 1 / SQRT (mAs)
- Tailor the protocol to the clinical question
  - *E.g.*: 30 mAs for sinus CT, FESS planning

    Mulkens et al, AJR May 2005

    Loubele et al, Radiat Prot Dosimetry 2005
  - *E.g.*: 30 mAs for pituitary CT, transphenoidal sx

170 mA

90 mA

Michael Lev, MGH

50% mAs Reduction? Slightly Noisier, but OK for F/U

- Dept wide study ↓ mA by 50% for all CT's
  - Unchanged HU, GW conspicuity
  - 22% decreased CNR (attributable to noise)

Mullins, Lev, Bove, O'Reilly, Saini, Rhea, Thrall, Hunter, Hamberg, and Gonzalez. Comparison of image quality between convnetional and low dose NCCT. AJNR Apr 2004

Optimizing Acquisition: Other Considerations

- Lower kV
  - Increased photoelectric effect
    - Higher HU iodin
- Adaptive Dose Modulation
  - Z-axis vs XY ("angular")
- Avoid rescanning same region
  - E.g., head and temporal bone, face and sinuses (*? billing*)
- Maximize quality parameters
  - Decrease motion artifact: speed, sedation
  - Remove extraneous hardware
  - Optimize contrast bolus; right sided
  - Angle gantry though clips, fillings

Brown, Lustrin, Lev, Taveras et al. AJR 1999

Adaptive Dose Modulation

- Varies mA with AP, lateral attenuations / diameters
- Noise index definition
  - … "approximately equal to standard deviation in the central region of the image when a uniform phantom is scanned and reconstructed"
- Substantial dose reduction for NCCT, CTA, C-spine
  - % decrease depends on baseline protocol

    Smith, Dillon, Wintermark et al. Radiology 2008
- More useful for neck than head, in our experience
  - Wide range of thickness in shoulders
  - Noise index values of 11.4 and 20.2, result in 20% and 34% dose reduction, respectively

    Russell, Anzai et al, Seattle. AJNR 2008

ASIR (GE), IRIS (Siemens): Adaptive Statistical Iterative Recon (MBIR --- Model Based Iterative Recon)

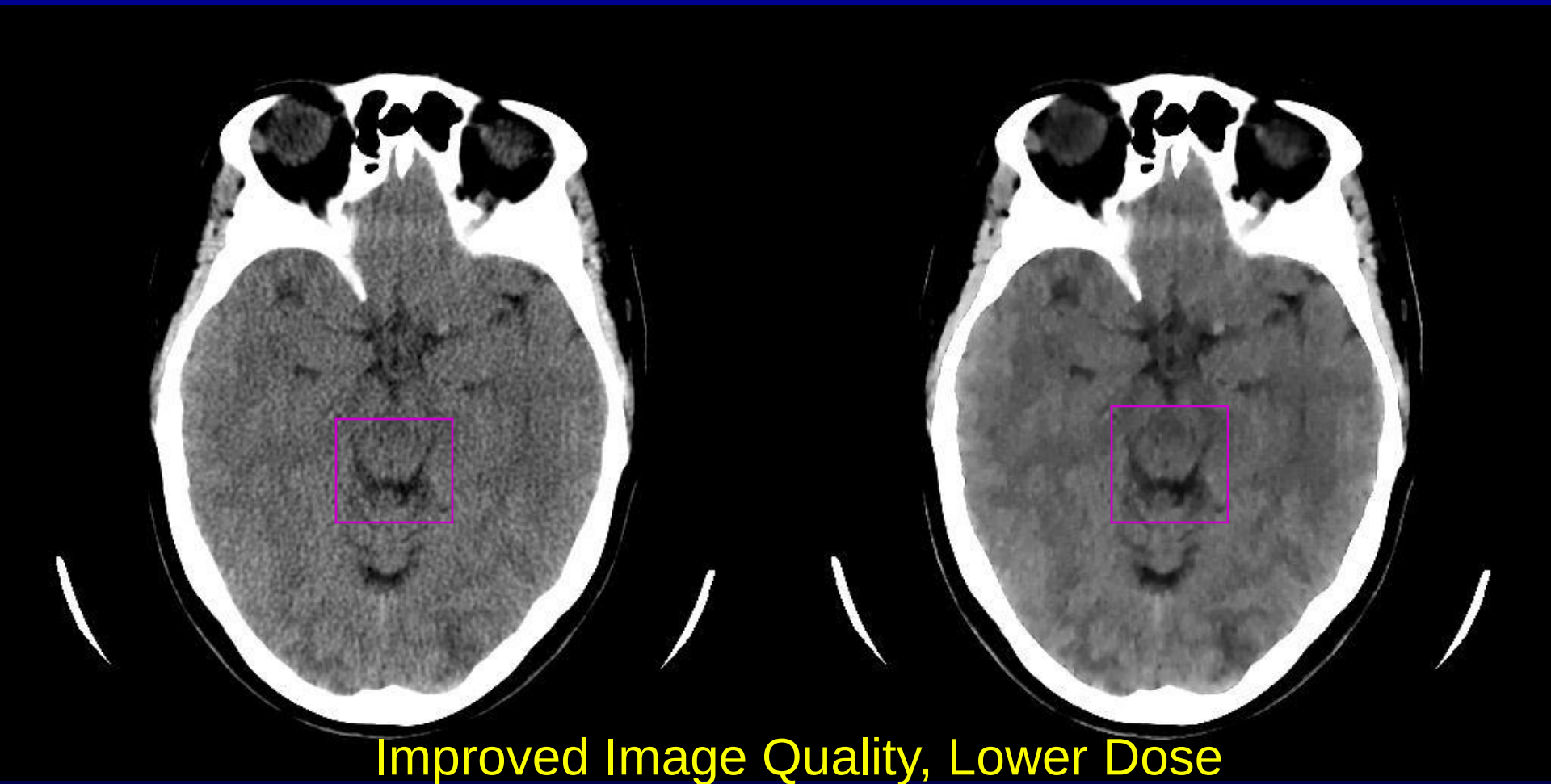

Improved Image Quality, Lower Dose

Courtesy of Shervin Kamalian and GE Healthcare

Sample CT Dose Reduction at 30% ASIR

HEAD

		kv	mA	Noise (ADM)	ASIR	Rot speed	Pitch	CTDIvol	DLP
Head I-&I+	Current	120	200		30%	0.7	0.531:1	49.7	932.25
	previous	120	250		0%	0.7	0.516:1	66.51	1270.34
CTA (Head)	Current	120	235		30%	0.5	0.531:1	41.18	733.57
	previous	120	350		0%	0.5	0.516:1	59.62	1170.17
CTA (H&N)	Current	120	min 350 max 600	13	30%	0.5	0.984:1	29.89	1333.86
	previous	120	min 350 max 600	10	0%	0.5	0.516:1	57.06	2518.04

SPINE

HD	kv	mAs (ADM)	ADM Noise	ASIR	Pitch	Rotate speed	CTDIvol	DLP	Thickness
C spine	140	Min 100 Max 715	11.83	30%	0.561:1	0.5	21.45	539.08	2.5
T/L spine	140	Min 100 Max 715	10	30%	0.984:1	0.5	10.11	246.59	0.6

VCT	kv	mAs (ADM)	ADM Noise	ASIR	Pitch	Rotate speed	CTDIvol	DLP	Thickness
C spine	140	Min 100 Max 715	20	0%	0.561:1	0.5	42.04	1056.46	0.6
T/L spine	140	Min 100 Max 715	20	0%	0.561:1	0.5	77.92	1860.57	0.6

Single vs Dual Energy CT

- A single CT Number (HU)
- Prior knowledge for material separation
- Unable to distinguish materials with same HU
  - Blood vs. dilute contrast
  - Blood vs. diffuse mineralization
  - Uric acid vs. Ca oxalate
  - Calcification vs. gouty tophus

Dual Energy Principles

- Total attenuation decreases with increasing energy
- Decrease is characteristic for each material
- Depends on photon energy and material density
- X-ray absorption depends on the inner electron shells
  - DECT is sensitive to atomic number and density
  - DECT is not sensitive to chemical binding

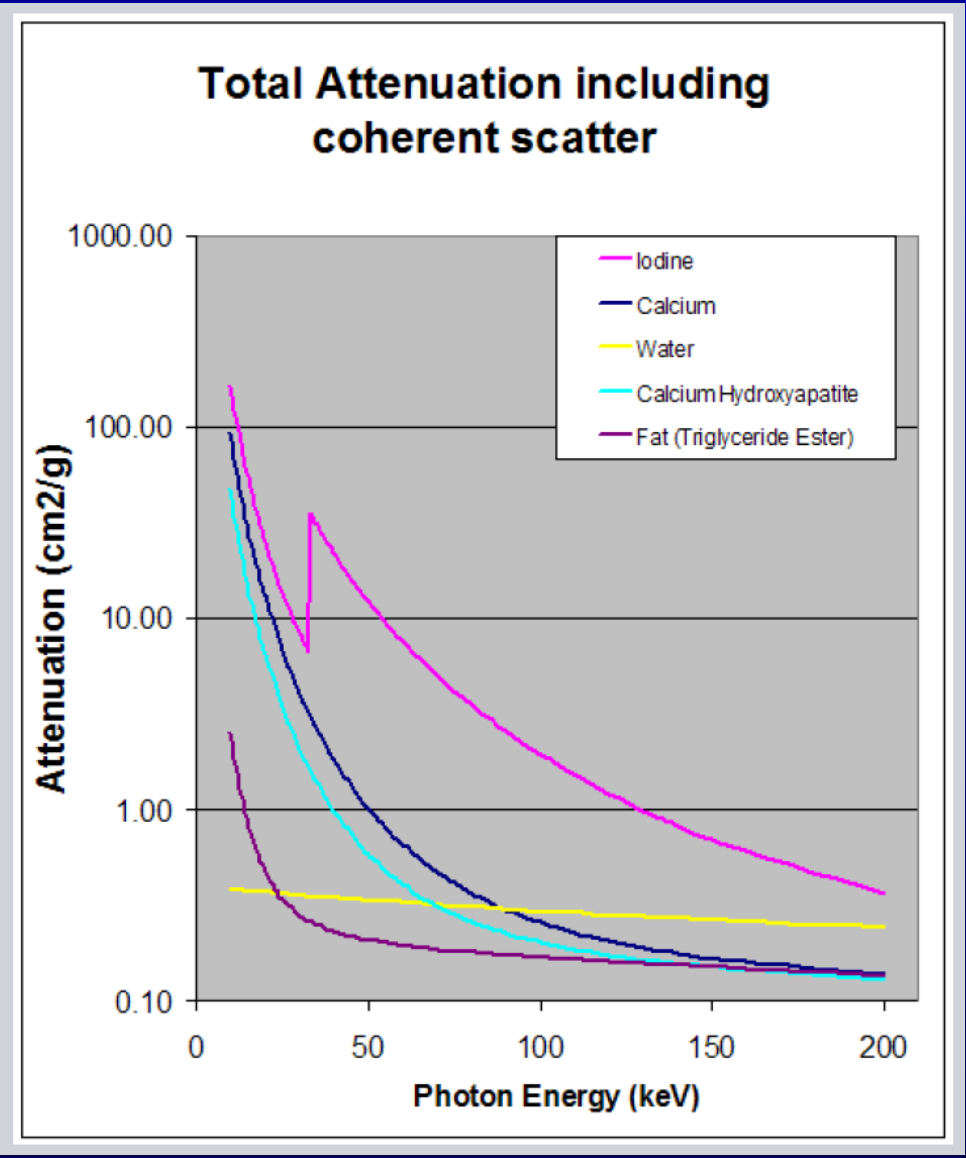

C. Leidecker, Siemens

Dual Energy Systems

Siemens: Dual Source CT (Definition)

- Two X-ray sources, two detectors, simultaneous acquisition
- Operate one source at 80kV and the other at 140kV

General Electric: Discovery Gemstone (HD-750)

- Single Source, single detector, on a fast gantry
- Rapidly alternate the single tube between 80kV and 140kV

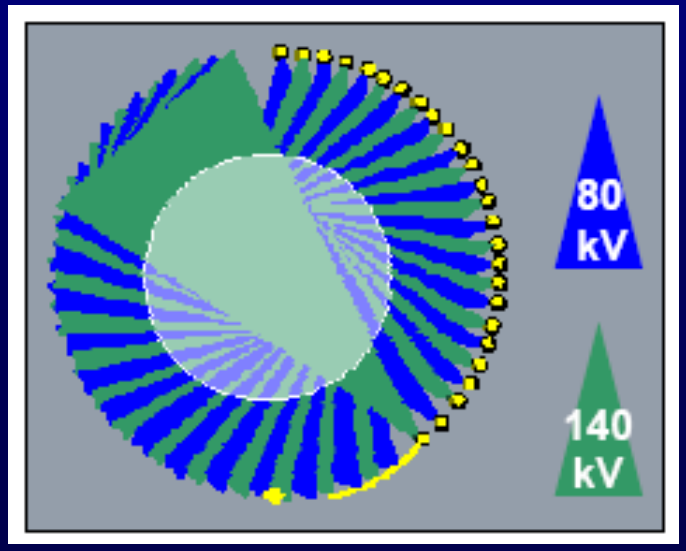

Dual Energy Systems: Pro and Cons

Siemens: Dual Source CT (Definition)

- Simultaneous acquisition
- Optimized tube current
- Projections: 90 deg apart
- One detector smaller than other

General Electric: Discovery Gemstone (HD-750)

- Projections close to each other in time => separation in projection domain
- Tube current constant (i.e., not optimized for each kV).

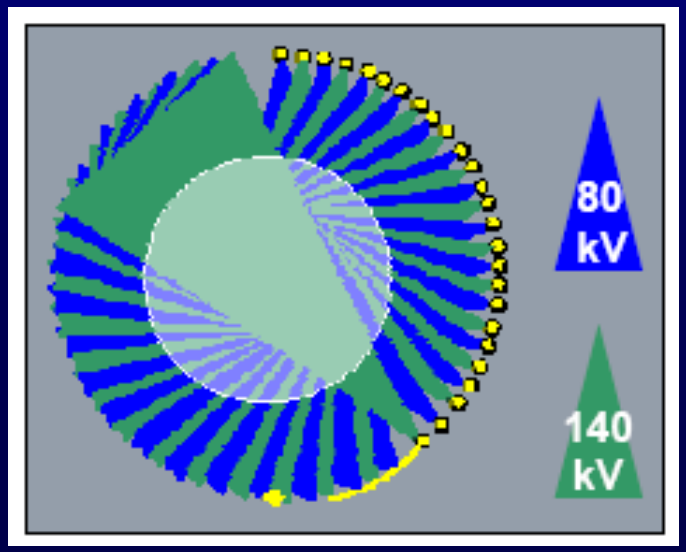

Application: Bone Removal

- **Automatic bone removal without user interaction**
- Intended use: base of the skull, carotids, runoffs…….

Courtesy of University Hospital of Munich - Grosshadern / Munich, Germany

Application: Calcified Plaque

- **Automatic bone removal without user interaction**
- Calcified plaques can be identified and „switched on and off“

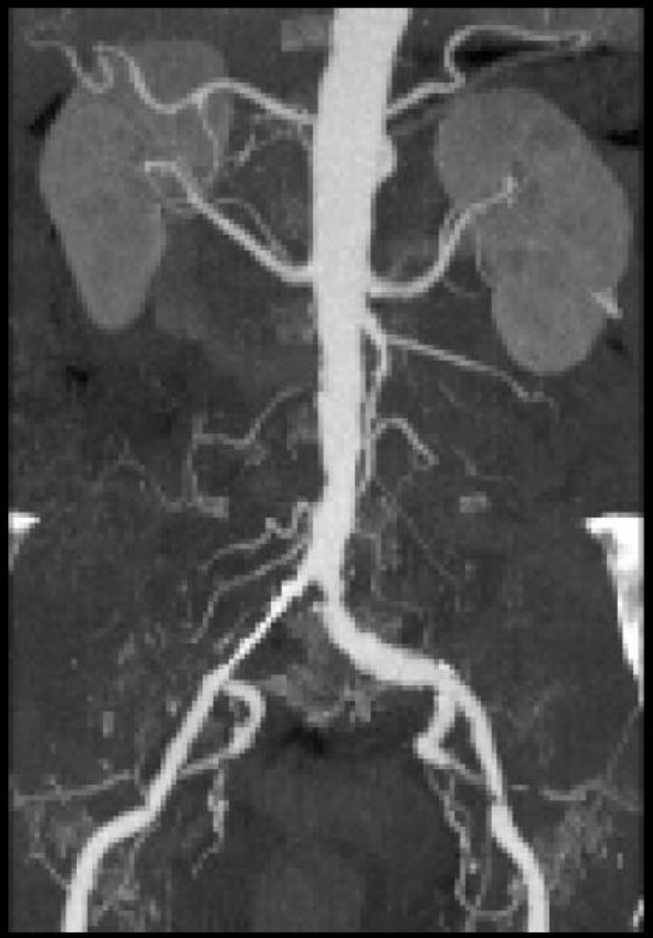

Courtesy of University Hospital of Munich - Grosshadern / Munich, Germany

Application: Kidney Stones

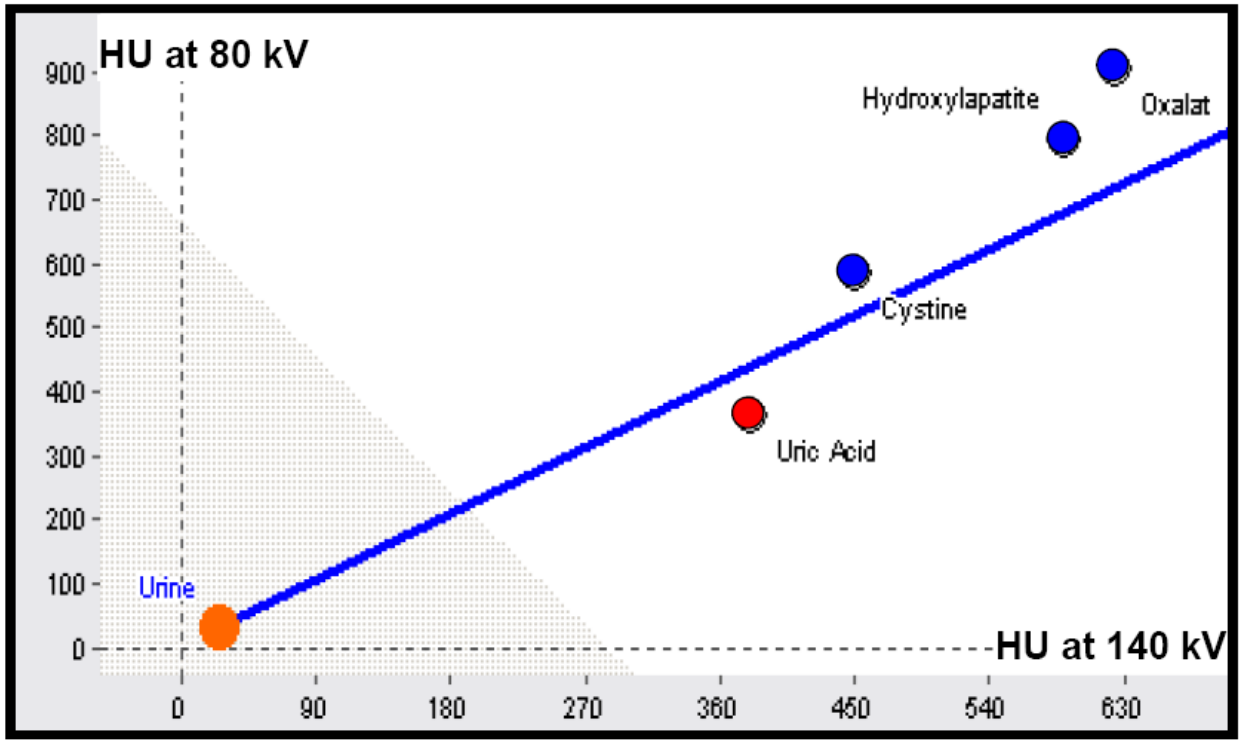

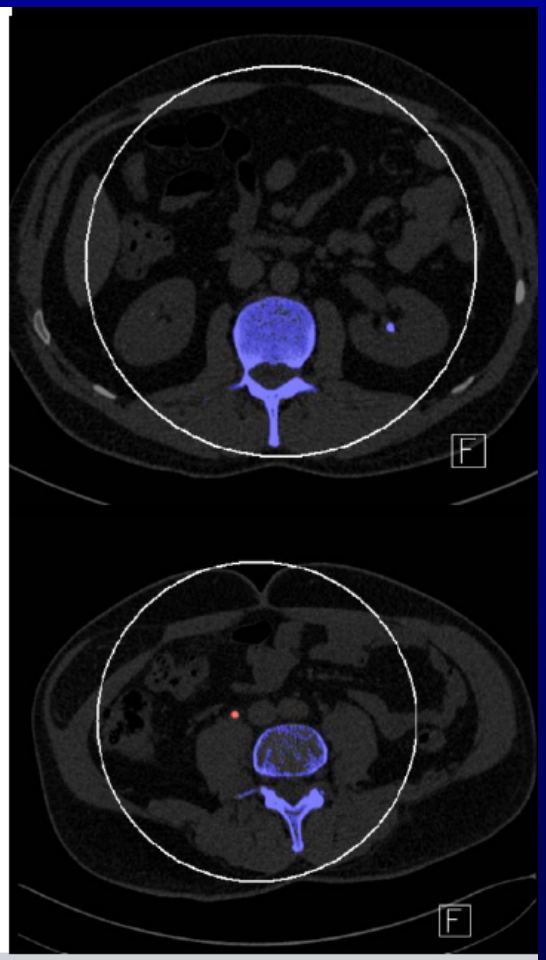

Courtesy of University Hospital of Munich - Grosshadern / Munich, Germany

- Uric acid stones can be differentiated from other renal calculi

Application: Gout

Dual Energy | Single Energy | T1W MRI

Gout Patient

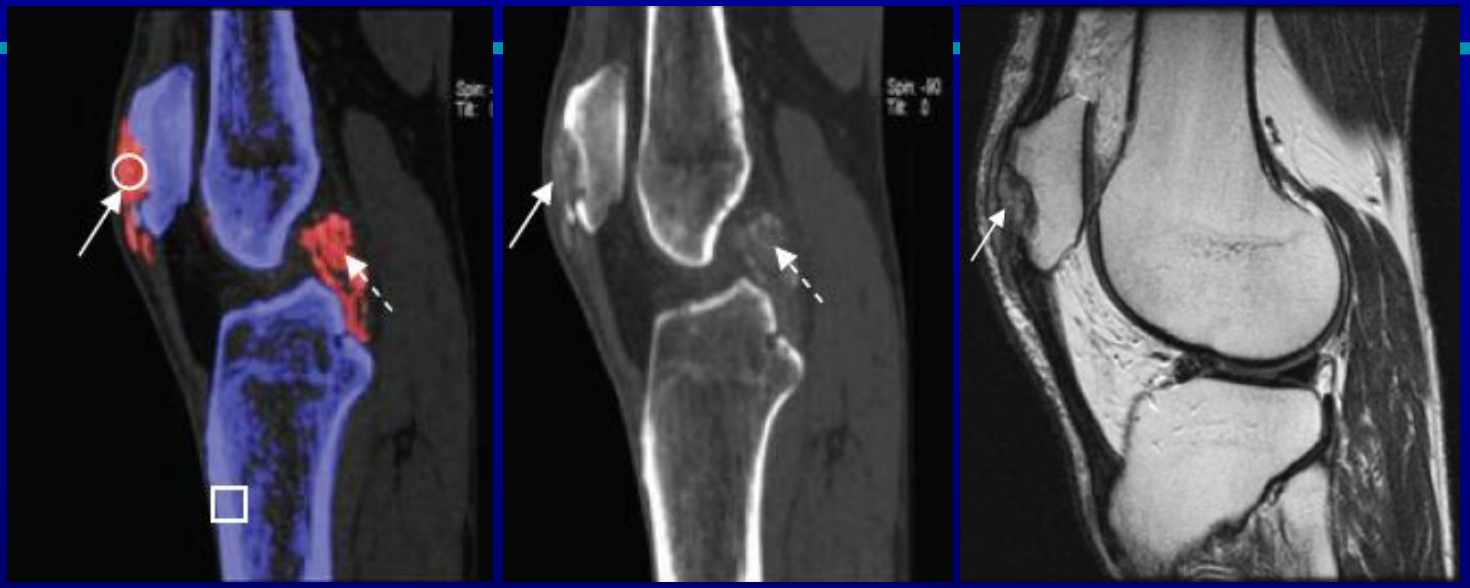

Healthy Control

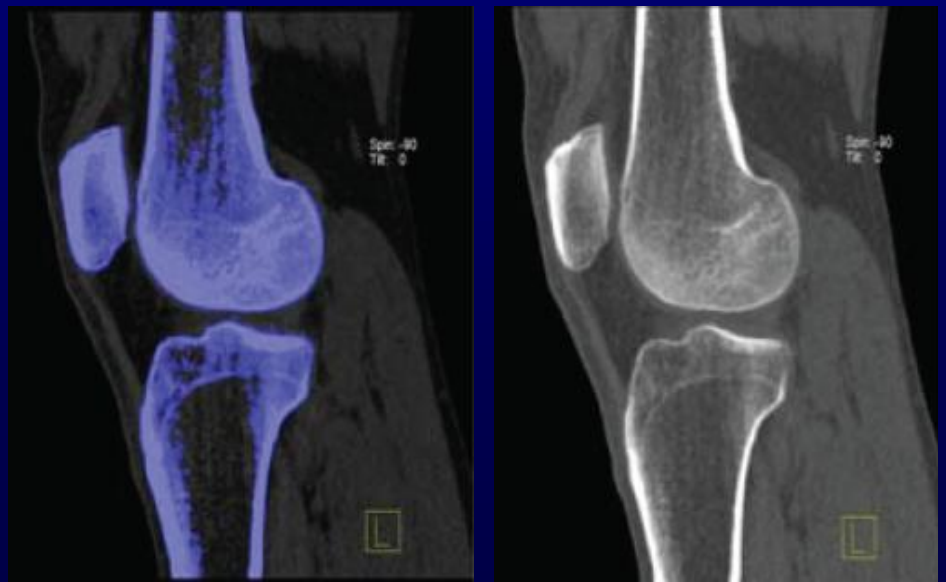

Hyon K. Choi,
Beth Israel Deaconess
Boston

Ultra-Low Dose Spectral CT Angiography

- Uses 0.625mm and 1.25mm slices from 12 sec helical study
- Excellent IQ with ultra-low dose (**14 mA**) and low 50ml iodine injection

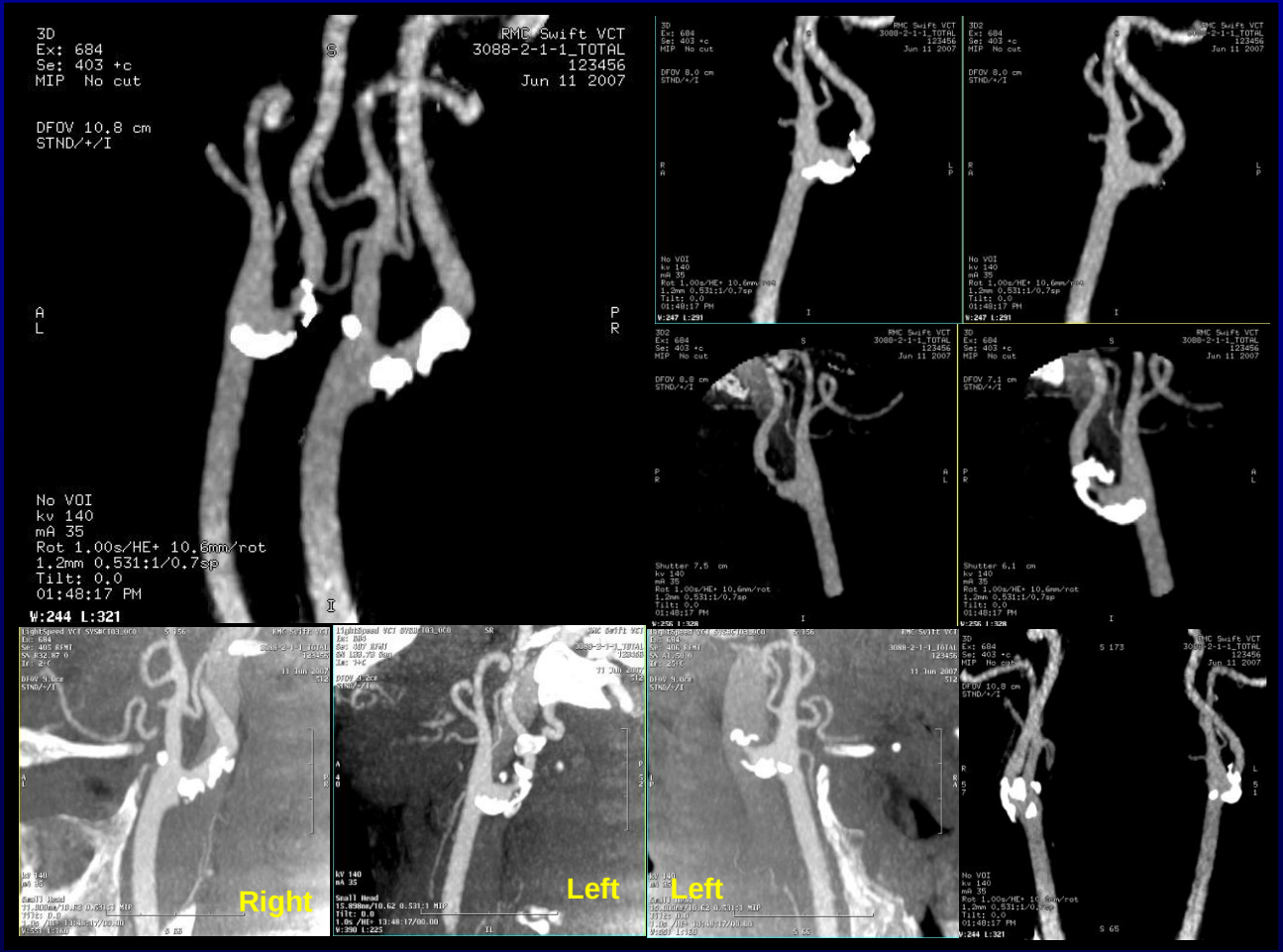

Images courtesy of GE and Rabin Medical Center, Israel

Posterior Fossa Beam Hardening Reduction

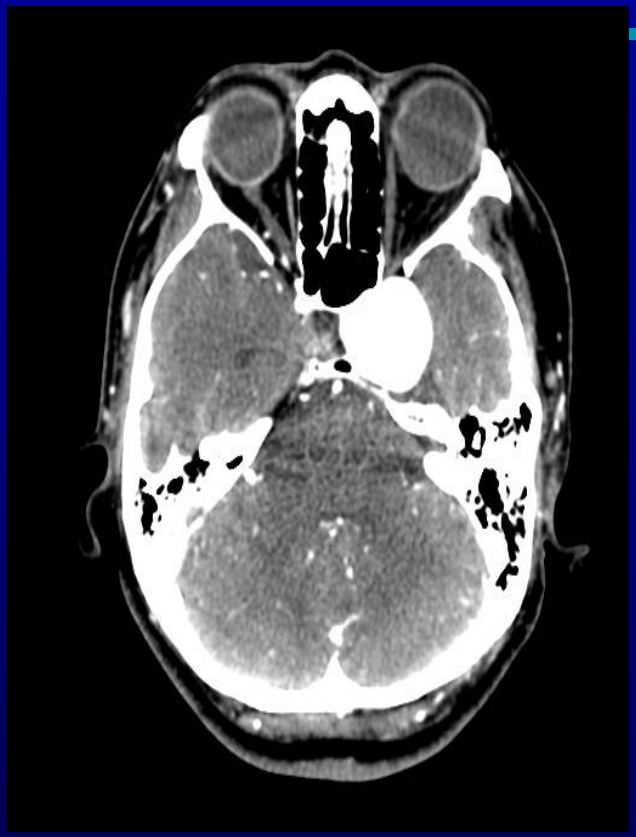

80kVp

140kVp

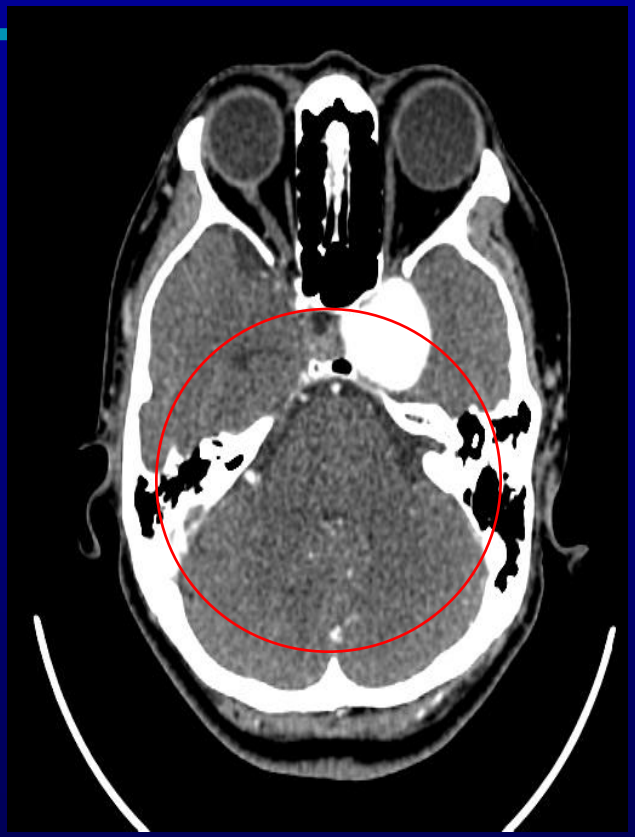

100keV

Xtream HD Console and GE LightSpeed Evaluation System

Courtesy of Dr. Amy Hara, Mayo Clinic Arizona

A Clinical Case

- 78 yo woman, acute onset of left hemiparesia
- MRI:
  - Right sub-insular infarct
  - Clot in the M1 segment of right MCA.
- Catheter-directed, intra-arterial embolectomy
- Post-procedure CT: Intracranial hyper-density
- Question: Is it contrast staining or hemorrhagic conversion of infarct?

Pre-procedure CT (single energy)

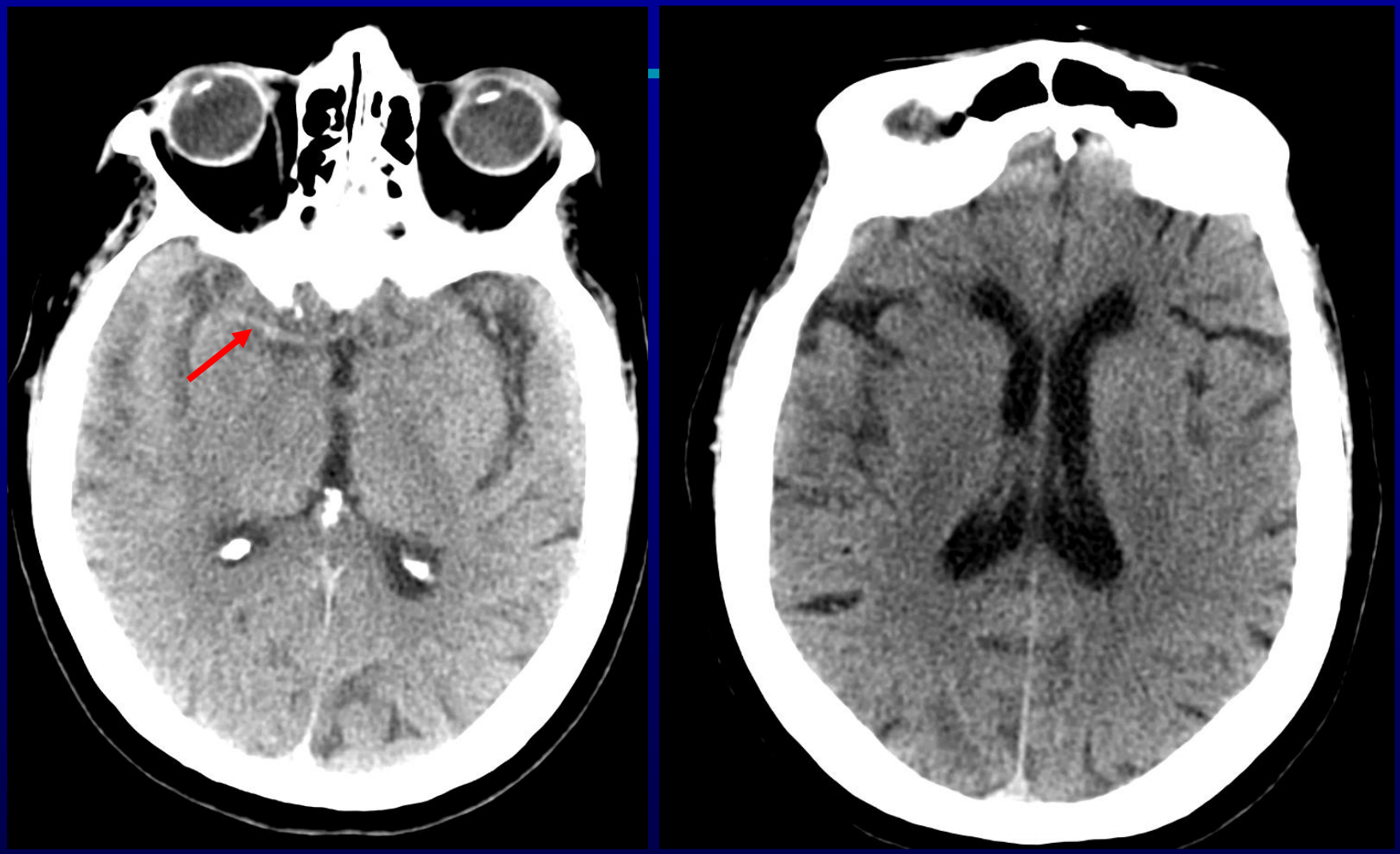

Initial Head CT: Hyperdensity in distal M1

Post-procedure single energy CT

Contrast staining or hemorrhagic conversion?

Post-proc DECT

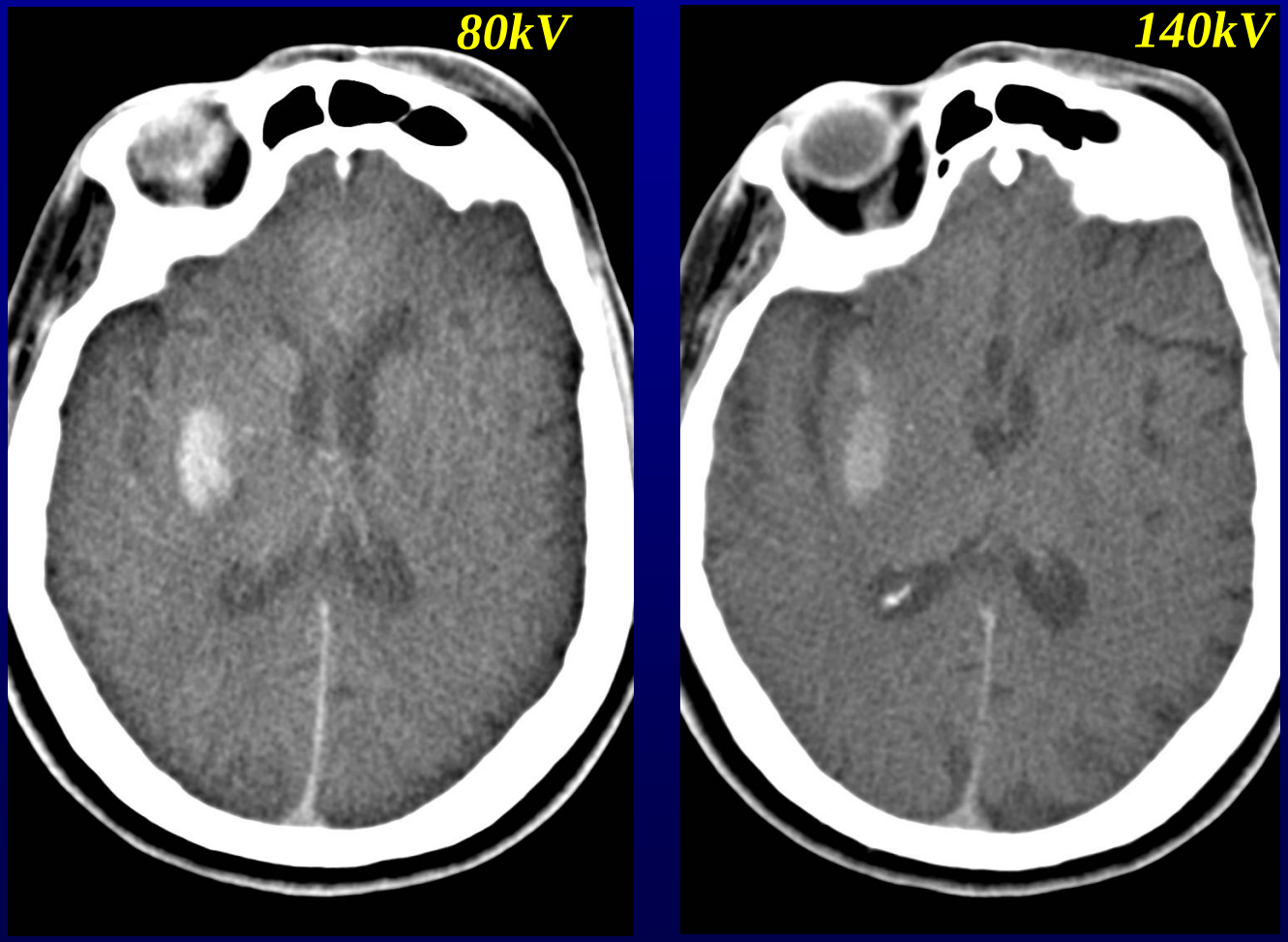

Question: Is it blood or contrast staining?

DECT Material Separation

Iodine Overlay

Virtual non-contrast Image

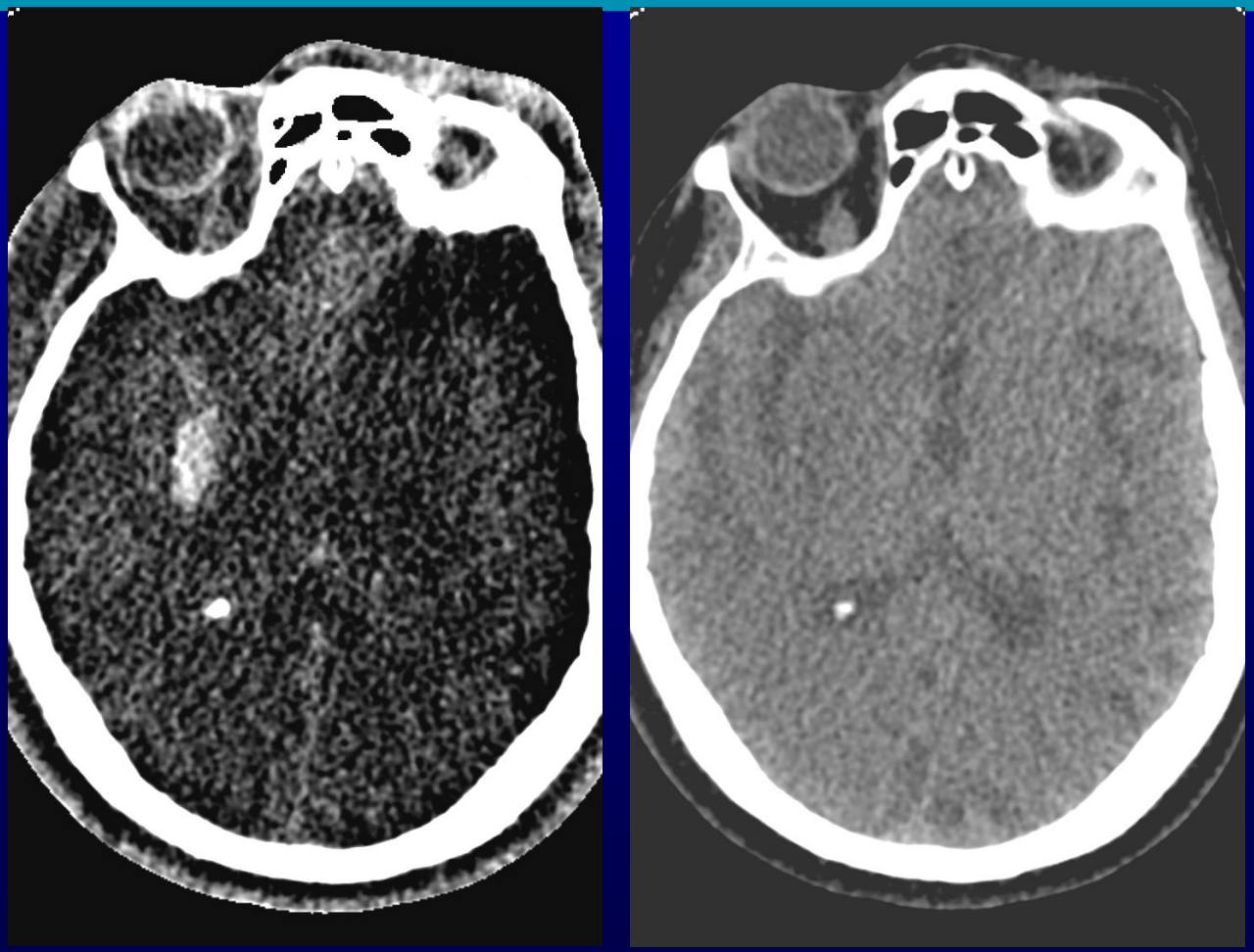

Contrast staining of infarct (ie, not blood)

MGH Head CT Take Home Points

- Dose well below ACR guidelines
- Configure protocol to the clinical need
- Avoid orbits if possible
  - Especially important in serial scans: ICU, pediatrics
  - *But don't* sacrifice diagnostic accuracy!
- Pediatrics
  - 125 mA used, < HALF the adult dose
  - Strategy: *screen* with low dose CT, *confirm* with MRI
  - Age < 18
- Axial vs helical mode?
  - Axial, arguably, has > SNR for otherwise fixed settings
  - No real speed advantage to helical
  - Helical = more reformat/recon options (e.g., coronals)
- Dual Energy CT
  - Effective tool for material discrimination
  - Quantitative tool
  - Both sensitive and specific for Hemorrhage vs. Iodine
  - Limited by saturation and other artifacts